



BMH Medical Journal 2015;2(2):44-46 **Case Report**

Eccrine Mucinosa Carcinoma: A Rare Indication for ER Estimation and Tamoxifen Therapy ? - A Case Report

Sandeep B Pillai, MS, DNB, MCh

Department of Surgical Oncology, Baby Memorial Hospital, Calicut

Address for Correspondence: Dr. Sandeep B Pillai, MS, DNB, MCh, Department of Surgical Oncology, Baby Memorial Hospital, Calicut. E-mail: drsandeeppillai@gmail.com

65 year old gentleman noticed a small swelling just below his lower eyelid on the left side. The swelling was apparently stable for about two months, and then it was found to be increasing. He consulted a local hospital, and the surgeon there advised excision biopsy of the lesion. The histopathological examination showed malignant eccrine lesion of the skin.

On examination, there was a 2 cm long transverse incision in the left infra orbital region with peri incisional induration and hyperpigmentation.

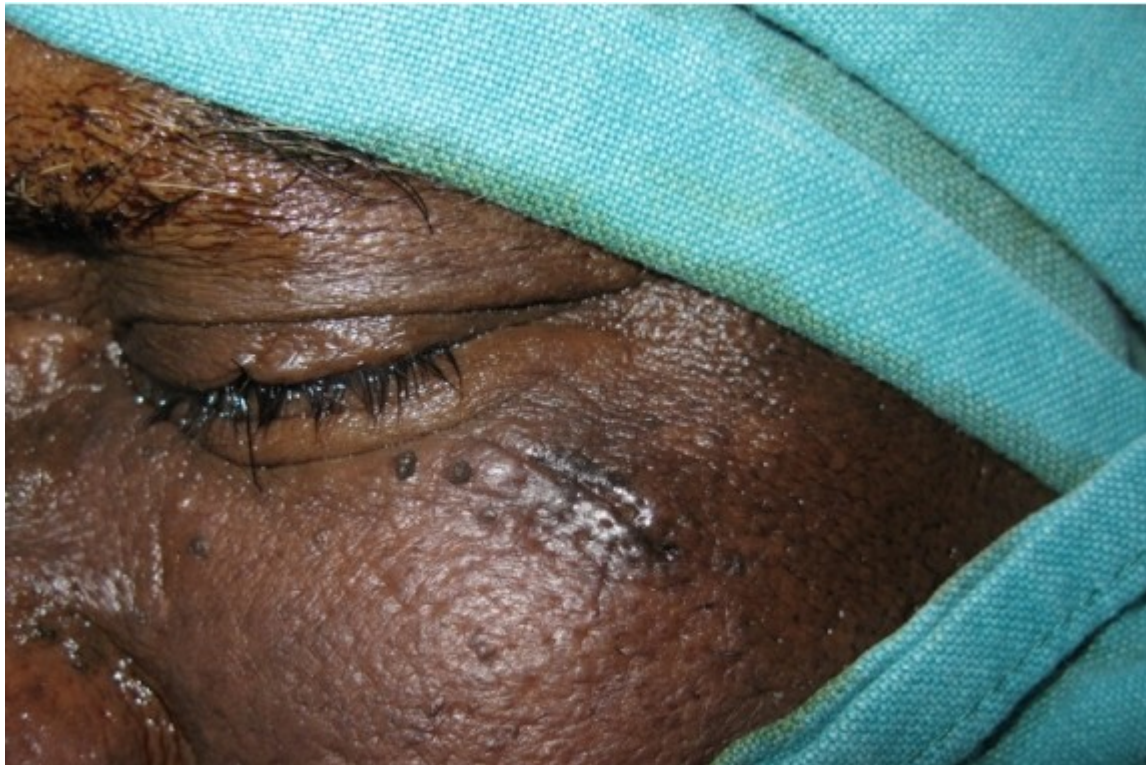

Figure 1: Scar with pigmentation left infraorbital region suggestive of residual disease

As the resection margins were not commended on and because there was some induration around the incision site suspicious of recurrence, we decided to go for a wider re excision of the lesion. After

obtaining informed consent and the necessary work up for anaesthesia clearance, he was taken up for the surgery under general anaesthesia.

Wide excision of the lesion with at least 1 cm clearance from all suspicious visible or palpable areas was attempted. The specimen was sent to frozen section for identifying any residual disease and for evaluation of adequacy of margins.

Frozen section examination revealed the presence of residual disease with extensive microscopic disease well beyond the grossly apparent extent of the disease. However, the tumor margins were free with at least 5 mm clearance.

The defect was purposefully devised in the form of a parallelogram to facilitate a rhomboid flap reconstruction as the area was cosmetically and functionally critical. The patient was discharged from the hospital the next day 2 with satisfactory wound condition with no flap necrosis or ectropion.

The final pathology report confirmed malignant eccrine mucinous neoplasm. In view of the rarity of the disease, the high recurrence rates after surgery alone, and various reports on adjuvant treatment with anti oestrogen therapy in some of these tumors due to their expression of estrogen receptors, we decided to do immunohistochemistry for ER expression.

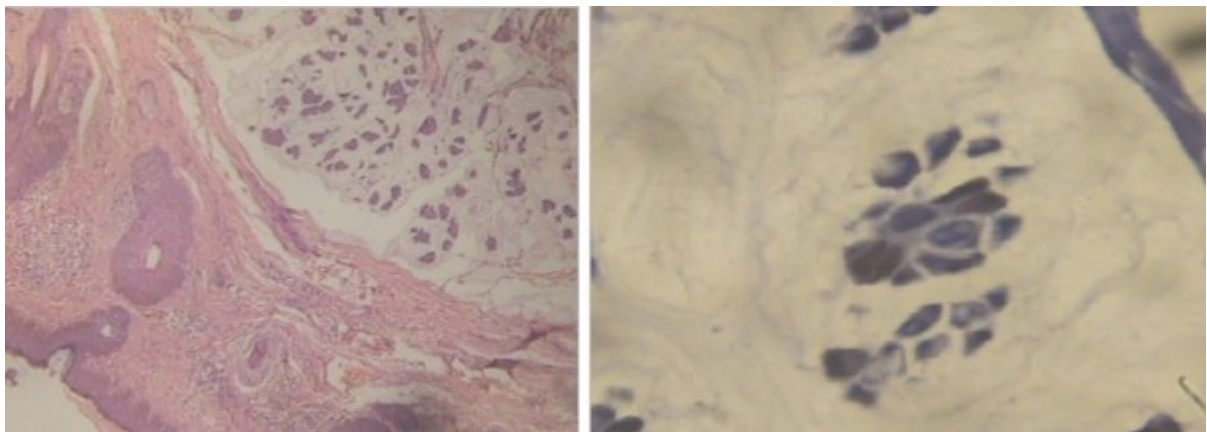


Figure 2: Left picture showing conventional HPR of eccrine mucinous carcinoma. Towards the right is the ER positive staining in IHC

The case was discussed in the comprehensive multidisciplinary tumour board. The possibility of the disease being metastatic, secondary to another primary elsewhere was discussed. Systemic evaluation for a probable primary was done, and was negative. It was then decided to start the patient on Tab. Tamoxifen 20 mg per day, and he was kept on regular 3 monthly follow up.

He was on regular follow up for about 2 years, after which he stopped tamoxifen due to discomfort probably attributed to the side effects of the drug. On his last follow up at 4 years, he was found to be free of locoregional recurrence and systemic disease.

Eccrine mucinous carcinomas are rare cutaneous malignancies with predilection to head and neck region, mainly near the eyelids and periorbital skin [1]. It is a malignancy of sweat gland origin, and with a high rate of local recurrence. One hundred and fifty nine cases have been reported in the literature so far [2]. It comes under a broad category of eccrine tumours of the skin. Commoner entities among this group are microcystic adnexal carcinoma, hidradenocarcinoma and eccrine porocarcinoma. Eccrine mucinous tumors are among the rarer forms of eccrine skin tumors [3]. They are well known to recur after incomplete excision, but rarely metastasise.

Skin tumours with eccrine differentiation often also express positive immunohistochemical staining for estrogen and progesterone receptors [4]. The positivity for estrogen receptors has important

clinical implications, in that affected patients may be offered endocrine manipulation as therapy [5]. Tamoxifen 10mg twice daily dose has been prescribed for ER positive tumours. The histopathology of mucinous tumors of skin is analogous to their counterparts in breast. Because of the inherent difficulty in differentiating primary eccrine tumours from cutaneous metastatic deposits from breast cancer, and many other tumors that produce mucinous deposits like cancers of lung, colon, kidney and prostate, a diligent clinical and radiological work up to rule out primary malignancy elsewhere is mandatory [5].

References

1. Kelly BC, Koay J, Driscoll MS et al; Primary mucinous carcinoma of the skin. *Dermatology Online Journal* 2008; 14(6):4.
2. Kamalpour L, Brindrise RT, Nodzinski M et al; Primary cutaneous mucinous carcinoma: a systematic review and metaanalysis of outcomes after surgery. *Jama Dermatology* 2014 Apr; 150(4): 380-4.
3. Anthony Wong MD, Eccrine mucinous tumors: Medscape reference emedicine.medscape.com/article/1101796
4. Karima IS, Toufiq H et al; Eccrine carcinoma : a rare cutaneous neoplasm. *Diagnostic Pathology* 2013; 8:15.
5. Bindra M, Keegan DJ, Guenther T et al; Primary cutaneous carcinoma of the eyelid in a young male. *Orbit* 2005; 24(3): 211-4.