



BMH Med. J. 2017;4(2):65-68 **Case Report**

A Case of Hybrid Carotid Revascularization

Hari Prasad, Ummer Karadan, Harilal Nambiar, Rajesh Muralidharan

Baby Memorial Hospital, Calicut, Kerala

Address for Correspondence: Dr. K. Ummer, MD, DM, II Unit Chief, Department of Neurology, Baby Memorial Hospital, Calicut, Kerala. E-mail: ummerneuro@yahoo.co.in

Abstract

Cerebral infarction attributed to extracranial carotid and vertebral artery disease is defined as clinical stroke with evidence of infarction on brain imaging associated with >50% stenosis or occlusion of an extracranial carotid or vertebral artery documented by noninvasive imaging or angiography. Radiation to the neck poses a high risk for developing carotid stenosis. Even though the standard treatment for extracranial artery stenosis is carotid endarterectomy (CEA), higher rates of cranial nerve injury and wound complications including infection limit CEA applications in patients with prior radiation. Carotid angioplasty and stenting (CAS) should be considered as an alternative to CEA for those patients with high surgical risk. We report a case of CAS in a patient who had prior neck radiation for malignancy, presenting with carotid stenosis.

Keywords: carotid stenting, hybrid revascularization

Introduction

After the North American Symptomatic Carotid Endarterectomy (NASCET) trial carotid endarterectomy was shown to be superior to best medical management with absolute risk reduction of 17% [1]. According to latest AHA/AAN guidelines any symptomatic carotid stenosis should undergo revascularization within 2 weeks, if the stroke is mild or if neurological status is improving [2]. The Carotid Revascularization Endarterectomy versus Stenting (CREST) trial showed similar short term and long term benefit from carotid endarterectomy and carotid stenting [3]. Post radiation stenosis is high risk for endarterectomy. Here we discuss our case of post radiation symptomatic carotid stenosis who underwent carotid stenting by hybrid approach.

Case Report

This elderly male with past history of left MCA infarct 1 year back, fully recovered, was able to walk unaided, with MRS of 0. He also had history of coronary artery disease and intermittent claudication in both lower limbs with feeble peripheral pulses. He then developed carcinoma base of tongue (moderately differentiated squamous cell carcinoma) with multiple lymph nodes in the neck, diagnosed 6 months back, for which he received 7 cycles of chemotherapy and 36 cycles of radiotherapy. Post radiotherapy he developed an acute infarct in the left MCA territory which was non-disabling. On evaluation he was found to have significant carotid stenosis as confirmed by CT angiography which showed multifocal moderate stenosis of left common carotid artery. Carotid

stenting through femoral approach was not feasible as he had occlusion of both iliac arteries and infra-renal aorta. Left brachial approach was also not successful due to acute angulation (**Figure 1**). With support from cardiothoracic surgeon and cardiologist, he was taken up for carotid stenting from axillary approach after surgical exposure of the axillary artery. Post stenting cerebral DSA was done, which showed normal flow across the carotids.

Our patient presented with symptomatic 65% carotid stenosis and resultant ischemic stroke which was non-disabling. He had NIHSS 1 and MRS 0. He has been on radiotherapy for carcinoma base of the tongue. He also had significant lymph nodes in the neck necessitating surgical exploration and chemotherapy. He had feeble pulses in both lower limbs, peripheral DSA done showed occlusion of infra-renal aorta, bilateral iliac arteries with profuse collateral formation which was confirmed by CT angiography. An endovascular procedure is ideal in this case but considering possibility of vasospasm, we opted for hybrid procedure. Cerebral DSA was done after exposure of right axillary artery by cardiothoracic surgeon, which showed left common carotid artery stenosis of 70%. Reinforced 7F long sheath was placed in right subclavian artery. SIM 1 catheter was used to catheterize left common carotid artery. 7F multipurpose catheter was slowly tracked over a guide wire after removing SIM 1 catheter. As stenting was not possible with this method, the long sheath was slowly telescoped over the 7F multipurpose catheter, and the latter was removed. Transend 0.10 microwire crossed the lesion and it was parked in the left petrous internal carotid artery. 8 x 40 mm Acculink stent was deployed under fluoroscopic guidance followed by post dilatation with Viatrac balloon (4.5 x 20 mm) to get 100% angiographic result. Post procedure long sheath was removed carefully over the wire and the arteriotomy sutured by cardiothoracic surgeon.

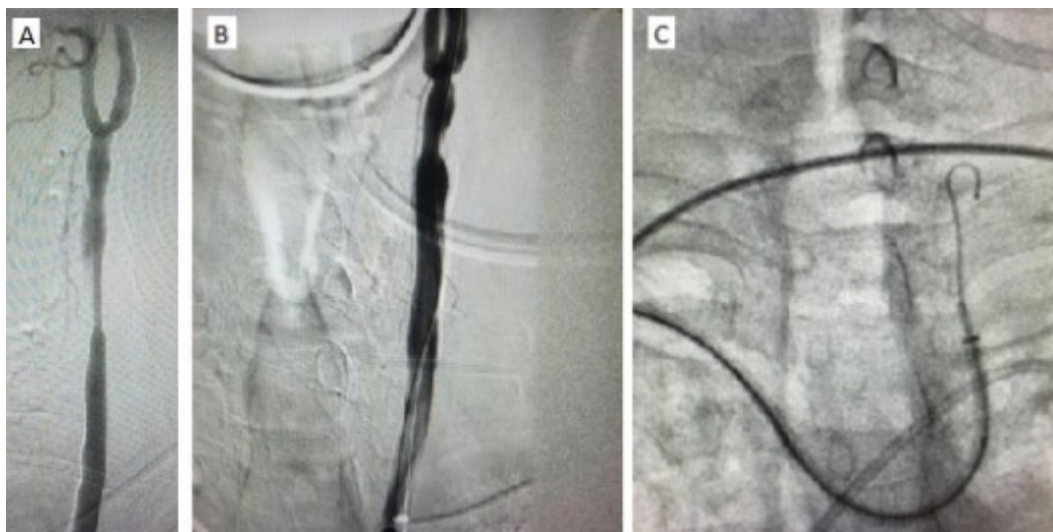


Figure 1: (A) DSA before the procedure showing significant narrowing of CCA. (B) DSA post procedure showing restored normal flow across CCA. (C) Acute angulation noted during left brachial approach. DSA: Digital Subtraction Angiography; CCA: Common Carotid Artery

Discussion

In our case despite concerns like age, post radiation stenosis, bilateral aorto-iliac occlusion, procedural complications like acute angulation on left brachial approach, possible spasm on right brachial approach, difficult wire manipulation in diseased carotid artery, he was stented without any postprocedural complications.

Cerebral infarction attributed to extracranial carotid and vertebral artery disease (ECVD) is defined as clinical stroke with evidence of infarction on brain imaging associated with >50% stenosis or occlusion of an extracranial carotid or vertebral artery documented by noninvasive imaging or angiography [2]. Prevalence of 50% carotid stenosis was 7% in women and 9% in men according to the Framingham Heart Study [4]. Cardiovascular Health Study showed that, 7% of men and 5% of women had moderate carotid stenosis, while severe stenosis was noted in 2.3% of men and 1.1% of women [5]. Subclinical carotid disease can also be associated with future stroke. ARIC

(Atherosclerosis Risk in Communities) study demonstrated that intima-media thickness (IMT) of the carotid artery predicted stroke even in those without ulcerated or hemodynamically significant plaques [6].

Radiation has been shown to be associated with significant carotid artery stenosis in a group nasopharyngeal carcinoma patients [7]. Radiation can induce and accelerate the increase in the IMT of the carotid arteries. The resulting carotid stenosis can lead on to transient ischemic attack or stroke [8]. Latent period from radiation to symptomatic carotid disease may vary from several months to even two decades. The latent period is apparently related to the diameter of the arteries involved [9]. Diagnosis can be made by Doppler ultrasonography, CT Angiography, MR Angiography or Digital Subtraction Angiography. As of date, digital subtraction angiography remains the gold standard for the diagnosis of carotid arterial stenosis. Even though the standard treatment for extracranial artery stenosis is carotid endarterectomy (CEA), higher rates of cranial nerve injury and wound complications including infection limits its use in post radiation patients. Carotid angioplasty and stenting (CAS) is a viable alternative to CEA for patients deemed to have high surgical risk [10]. Advantage of CAS over CEA in patients with previous radiotherapy is the absence of cranial nerve injury and wound complications.

Conclusion

Irradiation on the carotid area is a significant risk factor for developing carotid stenosis and subsequently cerebrovascular events. It has a great impact on the quality of life in survivors of head and neck malignancies. Age is not a contraindication for intervention. CAS is the preferred treatment method for symptomatic patients or those with severe carotid stenosis.

References

1. North American Symptomatic Carotid Endarterectomy Trial Collaborators. Beneficial effect of carotid endarterectomy in symptomatic patients with high-grade carotid stenosis. *N Engl J Med.* 1991 Aug 15;325(7):445-53.
2. Brott T G, Halperin J L, Abbara S. et al. ASA/ACCF/AHA/AANN/AANS/ACR/ASNR/CNS/SAIP/SCAI/SIR/SNIS/SVM/SVS guideline on the management of patients with extracranial carotid and vertebral artery disease: executive summary. A report of the American College of Cardiology Foundation/American Heart Association Task Force on Practice Guidelines, and the American Stroke Association, American Association of Neuroscience Nurses, American Association of Neurological Surgeons, American College of Radiology, American Society of Neuroradiology, Congress of Neurological Surgeons, Society of Atherosclerosis Imaging and Prevention, Society for Cardiovascular Angiography and Interventions, Society of Interventional Radiology, Society of NeuroInterventional Surgery, Society for Vascular Medicine, and Society for Vascular Surgery. *Circulation.* 2011;2011;124:489-532.
3. Mantese VA, Timaran CH, Chiu D, Begg RJ, Brott TG. The Carotid Revascularization Endarterectomy versus Stenting Trial (CREST) - Stenting versus Carotid Endarterectomy for Carotid Disease. *Stroke; a journal of cerebral circulation.* 2010;41(10 Suppl):S31-S34.
4. Fine-Edelstein JS, Wolf PA, O'Leary DH, et al. Precursors of extracranial carotid atherosclerosis in the Framingham Study. *Neurology.*1994;44:1046-50.
5. O'Leary DH, Polak JF, Kronmal RA, et al. Distribution and correlates of sonographically detected carotid artery disease in the Cardiovascular Health Study: the CHS Collaborative Research Group. *Stroke.* 1992;23:1752-60.

6. Chambless LE, Folsom AR, Clegg LX, et al. Carotid wall thickness is predictive of incident clinical stroke: the Atherosclerosis Risk in Communities (ARIC) study. *Am J Epidemiol.* 2000;151:478-87.
7. Lam WW, Leung SF, So NM, Wong KS, Liu KH, Ku PK, Yuen HY, Metreweli C: Incidence of carotid stenosis in nasopharyngeal carcinoma patients after radiotherapy. *Cancer* 2001; 92: 2357-2363.
8. Abayomi OK. Neck irradiation, carotid injury and its consequences. *Oral Oncol* 2004; 40: 872-878.
9. Murros KE, Toole JF. The effect of radiation on carotid arteries. A review article. *Arch Neurol* 1989; 46: 449-455.
10. Roubin GS, New G, Iyer SS, Vitek JJ, Al-Mubarak N, Liu MW, Yadav J, Gomez C, Kuntz RE. Immediate and late clinical outcomes of carotid artery stenting in patients with symptomatic and asymptomatic carotid artery stenosis: a 5-year prospective analysis. *Circulation.* 2001 Jan 30;103(4):532-7.