



BMH Med. J. 2017;4(2):76 **ECG Challenge**

Wide QRS Tachycardia

Syamkumar Divakara Menon

Associate Professor of Medicine, Faculty of Health Sciences, McMaster University, Canada

Address for Correspondence: Dr. Syamkumar Divakara Menon, MBBS, MD, DM, MSc, Associate Professor of Medicine, McMaster University, Hamilton, ON, Canada. Email: mdsmenon@gmail.com

Abstract

56 years old male patient presenting with palpitation to emergency room. On examination: tachycardic, BP 96/70. What is the diagnosis?

Keywords: wide QRS tachycardia, ECG

56 years old male patient presenting with palpitation to emergency room. On examination: tachycardic, BP 96/70. What is the diagnosis?

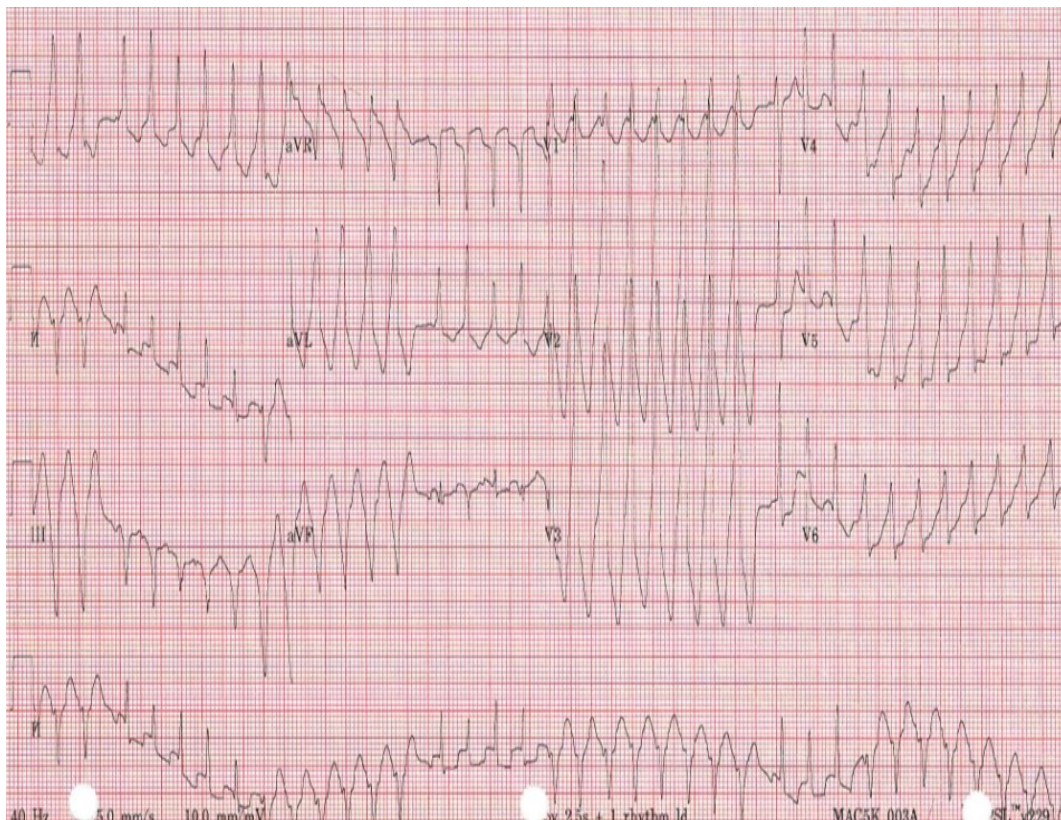


Figure 1

Please mail your answers to bhmj0@gmail.com. Correct answer and the names of those who give the correct answer will be published in the next issue of the journal.