



BMH Med. J. 2018;5(1):12-15 **Case Report**

A Case Of Tracheal Tumor Masquerading As Asthma

Shaik Mastan, Noufal Poongadan, A Preena, R Renju, CP Rauf

Chest Hospital, Kozhikode, Kerala, India

Address for Correspondence: Dr. Shaik Mastan, Chest Hospital, Kozhikode, Kerala, India. Email: mastansk84@gmail.com

Abstract

There are a variety of disease processes that either masquerade as asthma or contribute to worsening asthma symptoms in patients with asthma. Obstruction in the large airways of the chest commonly presents with expiratory wheezing and dyspnea, which is mistaken for asthma. Identifying the nature and location of the obstruction is essential because it may be a life-threatening process. We report a case of lower tracheal mass which was being treated as asthma with abnormal flow volume loop which was evaluated and turned out to be carcinoid tumor in the lower part of trachea.

Keywords: Tracheal Tumor; Masquerading As Asthma

Case Report

A 57 year old female presented to Out Patient Department with history of intractable dry cough and grade 2 dyspnea on exertion associated with wheeze of 3 months duration. There was no h/o fever, chest pain, chest tightness, hemoptysis, loss of weight, loss of appetite, hoarseness of voice, allergic rhinitis, bronchiectasis or tuberculosis. No family h/o of asthma or allergic rhinitis. On Examination she was afebrile, BP 120/70 mm Hg, PR 82/min, RR 20/min, no lymphnode enlargement or clubbing. Trachea was shifted to left with tactile fremitus on trachea during normal breathing, dull percussion note on left side of chest and low pitch polyphonic wheeze on right side with absent breathsounds on left side. Routine laboratory investigations and ECG were normal. Pulmonary function test (PFT) showed FEV1-19% of predicted FEV1, FVC-24% predicted and FEV1/FVC was 81% with no variation in post bronchodilator values (severe restriction) but flow volume loop (**Figure 1**) was abnormal, which was not consistent with flow volume loop described for intra thoracic or extrathoracic large airway obstruction. Chest X-ray showed collapse of left lung with ipsilateral shift of mediastinum (**Figure 2**). Bronchoscopy was advised; as patient was not willing a CT thorax and virtual bronchoscopy (**Figure 3, 4**) was done which showed distal tracheal mass almost occluding the complete lumen and filling left main bronchus causing collapse on left side. Patient was referred to a higher centre where the mass was removed using bronchoscopic snaring (**Figure 5**) with electrocautery and histopathology revealed it to be carcinoid tumour.

Discussion

Various causes of extra thoracic and intrathoracic obstruction of airways may masquerade as asthma. Vocal cord dysfunction a form of extrathoracic airway obstruction is commonly confused

with asthma. A list of other causes [1] of airway obstruction of the hypopharynx, larynx, and proximal trachea includes laryngeal spasm, lymph node enlargement, tumor, tracheomalacia, tracheal stricture and extrinsic compression. All of these conditions may present with dyspnea, wheezing and cough, which is localized to the throat or neck but can be perceived in the chest. Extrathoracic lesions tend to be more symptomatic with inspiration which can be depicted in flow volume loops, although combined inspiratory and expiratory obstruction can occur. Diagnostic procedure of choice for extrathoracic lesions is fiberoptic bronchoscopy along with laryngoscopy which helps in direct visualization of the airway and to confirm the site of obstruction.

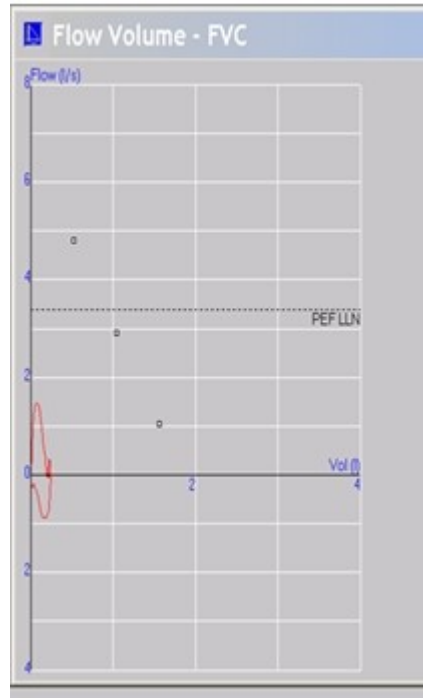


Figure 1: Pulmonary function test showing severe restriction but abnormal flow volume loop

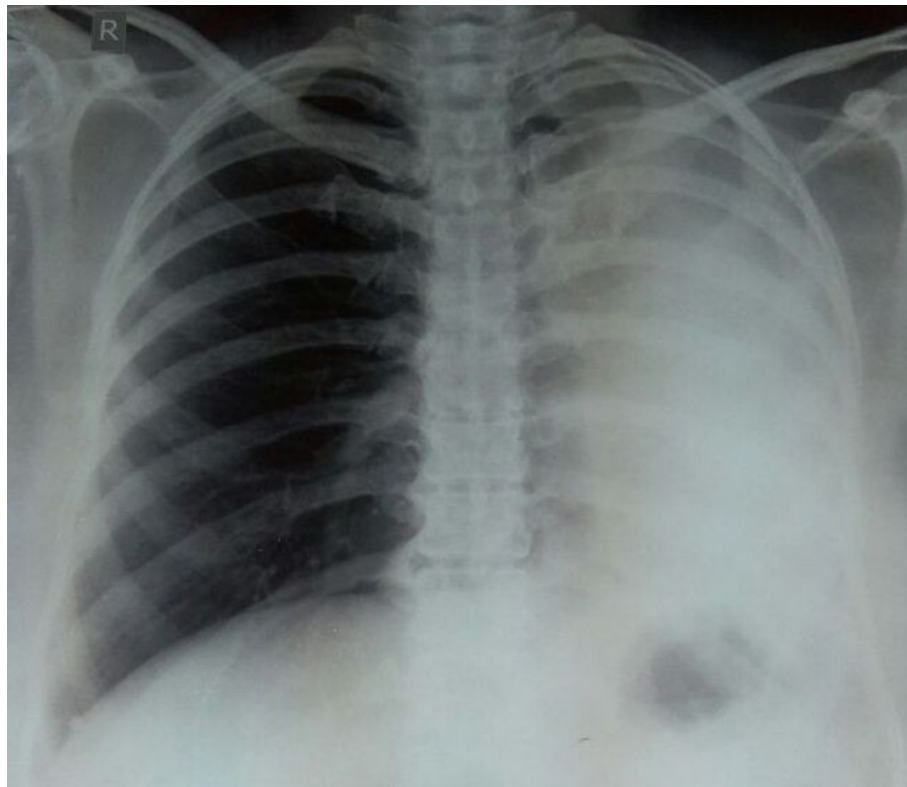


Figure 2: Chest x ray showing left side collapse with mediastinal shift

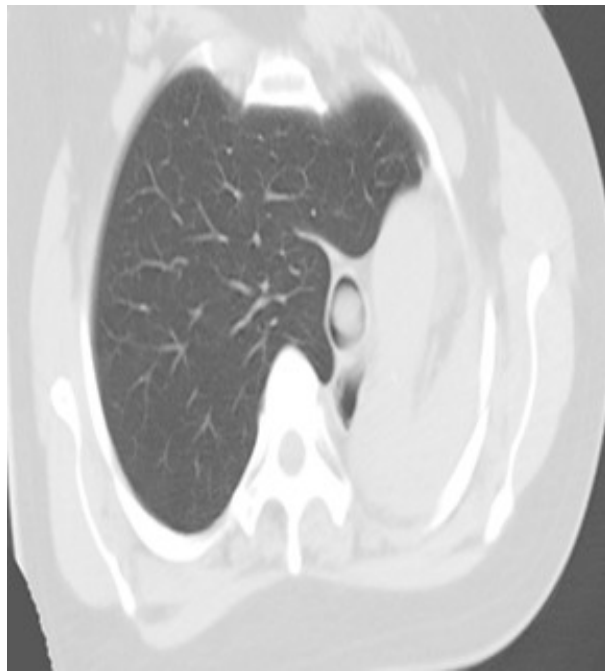


Figure 3: CT thorax showing intraluminal mass and collapse of left lung with hyperinflation of right lung




Figure 4: Virtual bronchoscopy showing near complete occlusion of tracheal lumen and left bronchus

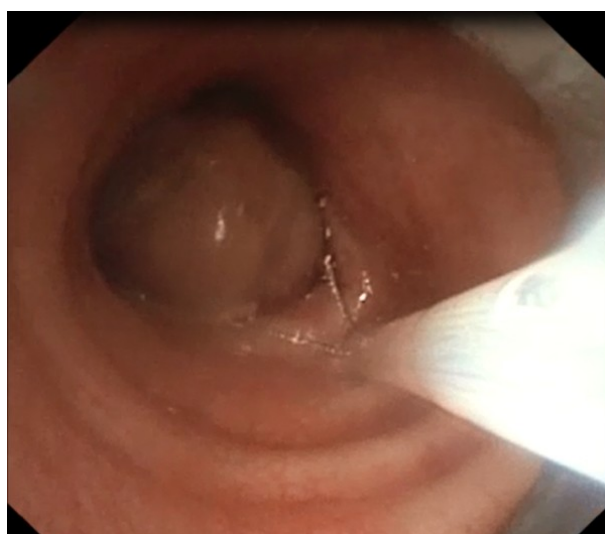

Figure 5: Bronchoscopic removal of tracheal mass using snare

(Picture courtesy: Dr. VR Pattabhi Raman, Consultant In Interventional Pulmonology And Sleep Medicine, Royal Care Super Speciality Hospital)

Clinicians should consider vocal cord dysfunction in any patient with a history of asthma and persistent symptoms after being treated. Visualization of the vocal cords, preferably while the patient is symptomatic is diagnostic feature of vocal cord dysfunction. Complete adduction of the vocal cords during inspiration, with formation of a posterior glottic 'chink' is diagnostic [2]. PFT shows airflow obstruction, with no significant bronchodilator response. Bronchoscopy is the procedure of choice for diagnosis, if necessary, thoracoscopic or open lung biopsy are done.

Symptoms and signs of airway obstruction due to other causes may masquerade as Asthma. Absence of these key diagnostic features should prompt further evaluation for other disorders that can present as asthma [3]. Our patient had cough, dyspnea and wheezing with lack of response for asthma treatment. PFT showed abnormal flow volume loop with FEV1/FVC ratio (81%) suggesting severe restriction which does not fit with either flow volume loops described for extrathoracic or intrathoracic large airway obstruction prompted further evaluation. Flow volume loop was very peculiar showing a sudden a rise and fall during both in expiration and inspiration. Chest X-ray showed collapse with ipsilateral shift followed by Chest CT and virtual bronchoscopy which revealed intraluminal tracheal mass almost occluding the lumen, which explains the sudden cessation of the flow both during inspiration and expiration in flow volume loop. Mass was removed using brochosopic snaring and electrocautery and turned out to be carcinoid. Metastatic tumor deposits from breast, colorectal, ovarian, renal, uterine, thyroid, testicular, nasopharynx, prostate and adrenal carcinomas have been reported to present as masqueraders of asthma. Bronchoconstriction with wheezing which may be due to bronchial carcinoid tumor or as the result of high circulating levels of serotonin and other mediators causing bronchoconstriction [1]. Chest radiographic findings may be normal or show collapse, hilar mass and mediastinal adenopathy. Computed tomography is sensitive in detecting and localizing the lesions but bronchoscopy is diagnostic and biopsy will eventually have diagnostic and prognostic significance in these centrally located lesions. Urine 5-hydroxyindoleacetic acid is an effective screening test in carcinoid tumors [1].

Acknowledgement

Dr. VR Pattabhi Raman, Consultant In Interventional Pulmonology And Sleep Medicine, Royal Care Super Speciality Hospital.

References

1. Tilles, Stephen A. Differential diagnosis of adult asthma. *Medical Clinics* 2006; 90 (1): 61-76.
2. King, Christopher S., and Lisa K. Moores. "Clinical asthma syndromes and important asthma mimics." *Respiratory care* 2008; 53(5): 568-582.
3. Kanagarajan, Karthikeyan, et al. "Endobronchial metastatic disease masquerading as bronchial asthma." *Chest Journal. Meeting Abstracts* 2005; 128 (4): 408S-a.