



BMH Med. J. 2020;7(3):75-80. **Case Report**

## Tarlov Cyst And CSF Leak - A Case Report And Review Of Literature

Suresh S Pillai, Swaroop Sujath

Division Of Spine Surgery - Dept. Of Orthopedics, Baby Memorial  
Hospital Calicut, Kerala, India

**Address for Correspondence:** Dr. Suresh S Pillai, MBBS, D. Ortho, MS (Ortho), DNB (Ortho), MNAMS, Spine Fellow (Chang-Gung University, Taiwan), AO Spine Fellow (Nottingham, UK), MCh (Ortho), Consultant Spine Surgeon, Baby Memorial Hospital, Kozhikode, Kerala, India. PIN: 673004. E- mail: sureshorth@googlemail.com

**Keywords:** Tarlov Cyst, CSF Leak

### Introduction

Dr. Isadore M. Tarlov has done extensive cadaveric study on terminal filum specimens and is credited with the first description of perineural cerebrospinal fluid cysts [1]. These cysts arise from the extradural space and the posterior nerve of the respective dorsal root ganglion and mere localized at the endoneural-perineural junction [1]. These cysts can present variably with body pain, leg pain, neurogenic claudication or sacral insufficiency fractures. Many a times, these are incidental findings on routine MRI. In persistently symptomatic cases surgery is an option. CSF leak is a common complication following cyst decompression. Here is such a case which failed conservative measures leading to surgical intervention & CSF leakage post-operatively. All these were managed successfully.

### Case Report

An elderly lady presented with low backache and radicular pain right lower limb for one year. She had neurogenic claudication as well. She was evaluated with X-ray and MRI of the lumbosacral spine. MRI showed multiple Tarlov cysts. MRI showed erosion of S3 with cyst wall eroding the sacrum into the pelvis. She was treated conservatively with analgesics, tricyclics and physiotherapy. She had temporary relief, but the pain recurred. So, surgical option was sought. She was further evaluated and taken up for surgery. Through a posterior approach the dura and the cysts were exposed after laminectomy. The cyst wall showed fibers under the sac. The sac was opened. No further fluid came out after the sac was emptied. Valsalva maneuver was tried to check for any CSF leak. So the fascia was closed in a water-tight fashion. The bony erosion was leading to the pelvis. The patient walked the next day, but after 5 days post surgery, the wound was soaked with clear fluid, CSF leak. So she was advised surgery again. Upon re-exploration, there was CSF in the opened sac. The defect was repaired with 7-0 Prolene, fat, fascia were used to over sew the defect. Post **Pillai**

operatively the patient was symptom free. She was mobilized after one week of surgery. Her wound healed and she returned to her normal activities.

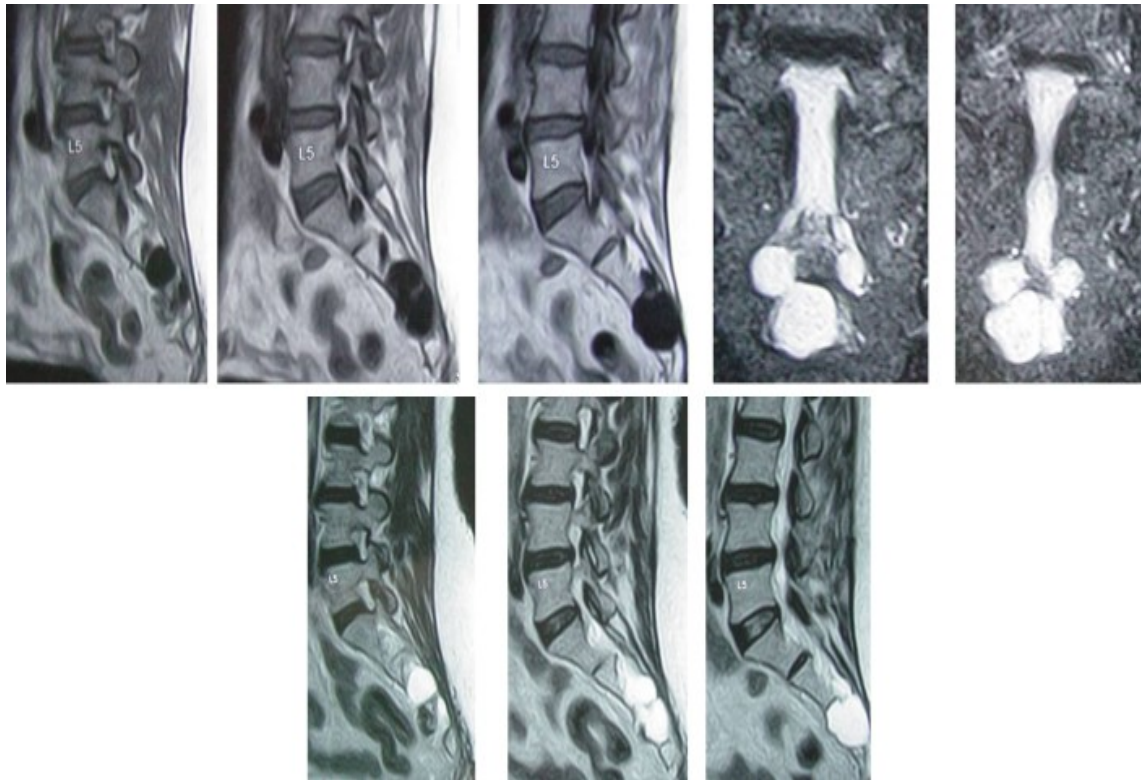


Figure 1: MRI showing Tarlov cyst and erosion of S3

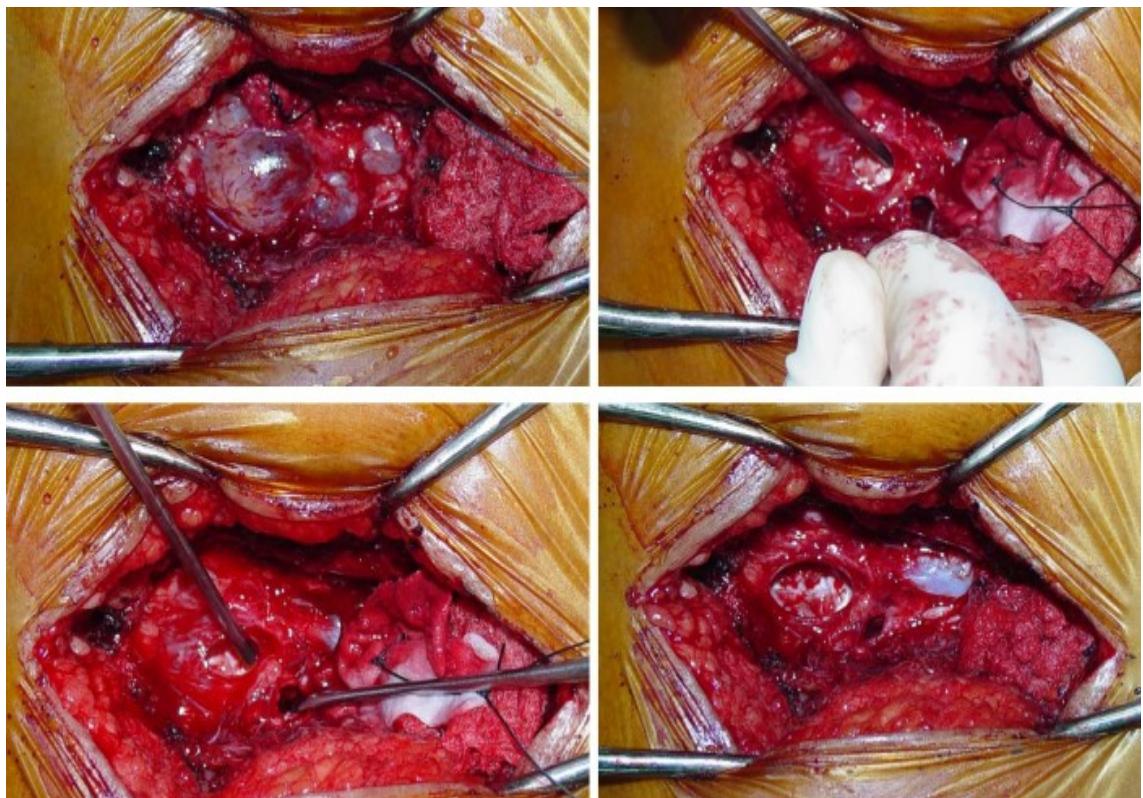
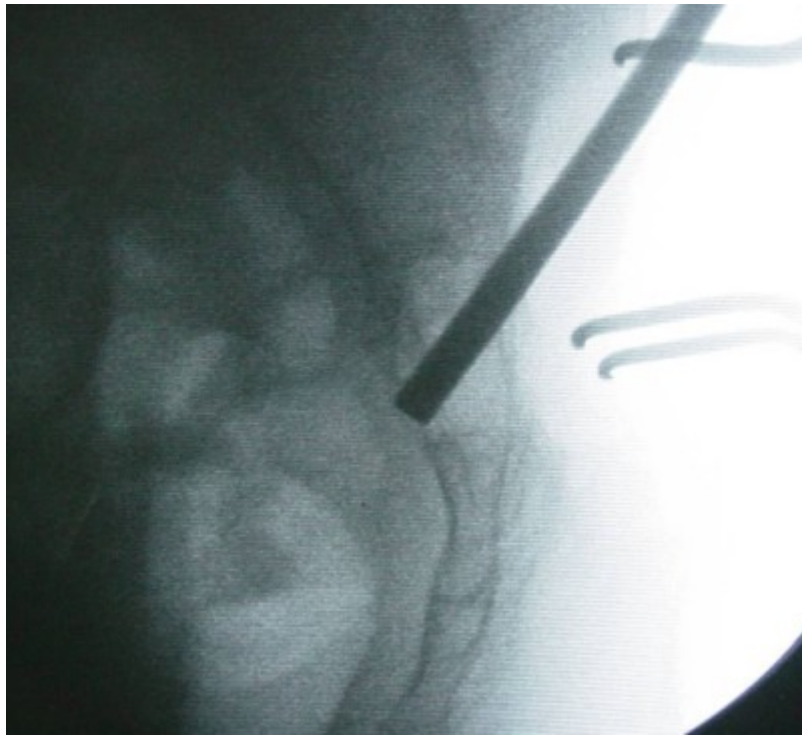
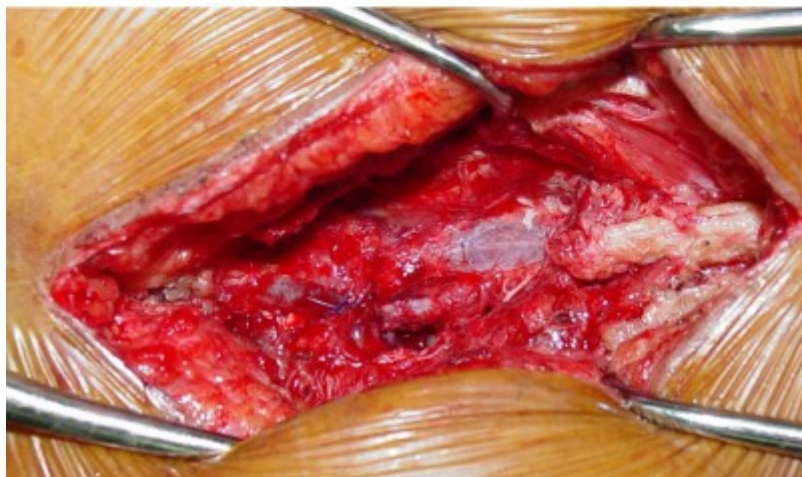
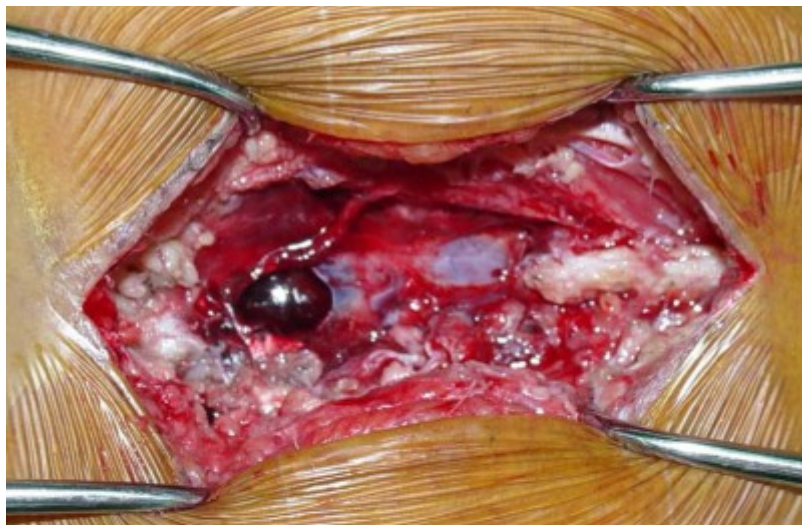


Figure 2: Intra-operative pictures showing cyst decompression



**Figure 3:** C-arm picture showing erosion of S3



**Figure 4:** Intra-operative pictures showing repair of the dura

## Discussion

The prevalence of Tarlov cyst is about 1-4.6% in adults. Tarlov cyst may present as sacral radiculopathy - sensory symptoms like dysesthesias, lower back pain, or neurogenic claudication [2-4] or sacral insufficiency fractures etc. History of these cysts is to enlarge leading to progressive symptoms. For unknown reasons there is a female predilection for Tarlov cysts. The popular explanation for perineural cyst development is secondary to micro communication between the cyst cavity and subarachnoid space especially at the endoneural - perineural junction of the nerve root dural sleeve. Here the pulsatile and hydrodynamic force contribute to development of one way ball-valve effect. CSF influx only permitted, causing gradual expansion of the cyst. The cyst is often seen at the junction of the posterior nerve root and dorsal root ganglion [5,6].

Goyal et al [7] classified intraspinal cysts into five categories:

1. Perineural cysts (nerve root diverticula or Tarlov's cyst)
2. Nerve root sleeve dilatations
3. Intradural arachnoid cysts
4. Extradural arachnoid cysts
5. Traumatic nerve root cysts

In 1988, Nabors et al classified spinal meningeal cysts into:

- Type I (Extradural meningeal cysts without spinal nerve root fibres)
- Type II (Extradural meningeal cysts with spinal nerve root fibres) ex: Tarlov's cyst
- Type III (Spinal intradural meningeal cysts)

These cysts are often detected during MRI examination. More than 70% of Tarlov's cysts are asymptomatic. These are well circumscribed masses. T1 weighted images reveal low signal and bright signal in T2 weighted images [8,9]. CT may be helpful in identifying insufficiency fractures and scalloping of the vertebrae. In late stages severe bony erosion of the vertebral body or neural foraminae are evident in plain x-ray films. CT scans 30-60 minutes after intrathecal administration of contrast can reveal delayed filling of meningeal cysts. Tarlov's cyst may appear at different or multiple locations, but usually it appears extradural immediately distal to the junction of the posterior nerve root and dorsal root ganglion [10]. Histopathologically nerve roots are found within the cyst wall in 75% of cases Tarlov cyst [11]. Nerve roots also may be seen in the cyst cavity.

Nerve conduction studies can reveal decreased sural nerve action potentials and sensory nerve conduction velocity loss [12]. Motor conduction are often normal, which indicate the location of Tarlov cyst adjacent to dorsal root ganglion.

Treatment of Tarlov cyst is based on clinical presentation. Conservative treatment with NSAID's, tricyclics and physiotherapy may be tried initially. Persistent symptoms may warrant surgical intervention by CSF flow diversion or surgical decompression. CSF flow diversion include percutaneous cyst drainage, percutaneous fibrin glue drainage, cyst-peritoneal shunt, lumboperitoneal shunt etc. Long term results are better with surgical decompression [13]. Laminectomy via posterior approach and excision of the cyst and imbrication [14] (suturing of the cyst wall).

CSF leak, infection and neurological deficits are the potential complications following surgery. Fibrin glue, muscle and fat graft etc may be used to seal any dural defects. CSF leak is the most common complication [10].

The cyst recurrence rate is about 0-10% [10]. Symptomatic improvement is obtained in 38-100% of cases following surgery.

### **Conclusion**

Tarlov’s cyst results from congenital weakness, trauma or inflammation of the dura matched with disturbance of CSF hydrodynamics. Surgical decompression & imbrication of the cyst gives good results. CSF leak is the most common complication which can be managed with fat graft, fibrin glue, direct repair or lumbar CSF drainage.

### **References**

1. Tarlov IM. Perineural cysts of the spinal nerve roots. *Arch Neurol Psychiatry* 1938;40:1067-74.
2. Schreiber F, Haddad B, Lumbar and sacral cysts causing pain. *J Neurosurg* 1951.8.5.0504.
3. Chaiyabud P, Suwanpratheap K. Symptomatic Tarlov cyst: report and review. *Med Assoc Thai*. 2006 Jul;89(7):1047-50.
4. Prashad B, Jain AK, Dhammi IK. Tarlov cyst: Case report and review of literature. *Indian J Orthop* 2007; 41:401-3.
5. Nabors MW, Pait TG, Byrd EB et al. Updated assessment and current classification of spinal meningeal cysts. *J Neurosurg*. 1988 Mar;68(3):366-77.
6. Neulen A, Kantelhardt SR, Pilgram-Pastor SM et al. Microsurgical fenestration of perineural cysts to the thecal sac at the level of the distal dural sleeve. *Acta Neurochir (Wien)*. 2011;153:1427-34.
7. Goyal RN, Russell NA, Benoit BG et al. Intraspinal cysts: a classification and literature review. *Spine (Phila Pa 1976)*. 1987; 12(3):209-13.
8. Lee JY, Impekoven P, Stenzel W et al. CT-guided percutaneous aspiration of Tarlov cyst as a useful diagnostic procedure prior to operative intervention. *Acta Neurochir (Wien)*. 2004;146(7):667-70.
9. Murphy KJ, Nussbaum DA, Schnupp S et al. Tarlov cysts: an overlooked clinical problem. *Semin Musculoskelet Radiol*. 2011;15(2):163-7.
10. Guo D, Shu K, Chen R et al. Microsurgical treatment of symptomatic sacral perineural cysts. *Neurosurgery*. 2007;60(6):1059-65.
11. Voyadzis JM, Bhargava P, Henderson FC et al. Tarlov cysts: a study of 10 cases with review of the literature. *J Neurosurg*. 2001;95(1 Suppl):25-32.
12. Cattaneo L, Pavesi G, Mancina D et al. Sural nerve abnormalities in sacral perineural (Tarlov) cysts. *J Neurol*. 2001;248(7):623-4.

13. Acosta FL, Quinones-Hinojosa A, Schmidt MH et al. Diagnosis and management of sacral Tarlov cysts. Case report and review of the literature. *Neurosurg Focus* 2003;15(2):E15.

14. Tanaka M, Nakahara S, Ito Y et al. Surgical results of sacral perineural (Tarlov) cysts. *Acta Med Okayama*, 2006;00-65-70.