



BMH Med. J. 2022;9(2):38-43. **Case Report**

Uterine Carcinosarcoma - A Rare Case Report

Rabiyabi V, Shaji K Ayillath, Ani Praveen, Athira Rani S

Baby Memorial Hospital, Kozhikode, Kerala, India

Address for Correspondence: Dr. Athira Rani S, Baby Memorial Hospital, Kozhikode, Kerala, India. E mail: athirarani.93@gmail.com

Abstract

Uterine carcinosarcomas are rare tumors comprising less than 1% of uterine malignancies. Uterine carcinosarcomas are extremely aggressive undifferentiated carcinomas which include both carcinomatous and sarcomatous elements. The prognosis is often poor, with 30-40% of cases having extrauterine involvement at the first presentation. The clinical presentation of the uterine carcinosarcomas is nonspecific, and imaging and pathology studies play an important role in diagnosis. We herein present a case of an elderly lady who presented with postmenopausal bleeding and was found to have carcinosarcoma of uterus.

Keywords: Carcinosarcoma, Postmenopausal bleeding

Case Report

An elderly postmenopausal woman, para 3, living 3, with 3 full term normal deliveries presented with a single episode of profuse bleeding per vagina that lasted for 4 days. She had history of loss of weight and loss of appetite for past 1 month. No history of breathlessness, headache, seizures, jaundice or bone pain. No history of urinary or bowel symptoms. She had history of Carcinoma anal canal (Poorly differentiated squamous cell carcinoma) with inguinal lymph node metastasis a decade back. For this she underwent Chemoradiation (2 cycles of chemotherapy with Mitomycin and 5FU and concurrent radiotherapy for five weeks) and was under regular follow up in radiotherapy OPD.

On examination, her vitals and general examination findings were normal. Per abdomen there was no mass palpable. On local examination there was excoriation of perineal skin (probably due to previous radiotherapy). Per speculum revealed normal cervix and vagina. Bimanual pelvic examination revealed bulky uterus. Laboratory blood investigations were unremarkable.

Ultrasound of pelvis showed a bulky uterus with well circumscribed lobulated heterogeneously hypoechoic lesion of size 47 x 46 x 30 mm occupying the endometrial cavity. A subsequent MRI Pelvis showed heterogeneously enhancing ill defined mass in endometrial cavity with restricted diffusion, invading myometrium at the fundal region, with significant thinning of myometrium and outer band of myometrium is continuous. Lesion closely abutting the posterior lip of cervix - likely Carcinoma endometrium.

Fractional curettage and biopsy cervix was performed. Histopathology report came as

Carcinosarcoma of endometrium. Hence we proceeded with Staging Laparotomy. Intraoperatively we found that the uterus was bulky, bilateral tubes and ovaries were normal, right pelvic lymph node was enlarged to 1.5 x 1.5cm, para aortic lymph node was enlarged to 1 x 1 cm, dense adhesions between posterior wall of uterus to rectum, post radiotherapy changes noted in POD and sigmoid colon. Surgery done was radical hysterectomy, bilateral salpingo oophorectomy, bilateral pelvic lymph node dissection, para aortic lymph node sampling and infracolic omentectomy. During post operative period she developed paralytic ileus which was symptomatically managed and she was discharged on day 14.

Histopathology report revealed an infiltrating neoplasm composed of biphasic component. Tumor showed epithelial cells in glandular and cribriform pattern. Heterogenous elements like immature cartilage - Chondrosarcoma, adipocytes lined by atypical lipoblasts - liposarcoma were present. Tumor invading more than half of myometrium, endocervical stroma, bilateral parametrium and lymphovascular invasion. Endometrium showed intraepithelial carcinoma. Right pelvic lymph node showed tumor deposits. Left pelvic lymph node, para aortic lymph node, vaginal cuff, serosa, omentum and peritoneal washing were free of tumor. The tumor was therefore diagnosed as carcinosarcoma. Based on FIGO staging of endometrial carcinoma this tumor belongs to Stage III C 1.

A subsequent FDG PET scan was done after 3 weeks and was found to have no distant metastasis. Currently she is advised to take 6 cycles of chemotherapy with Paclitaxel and carboplatin followed by vaginal brachytherapy.

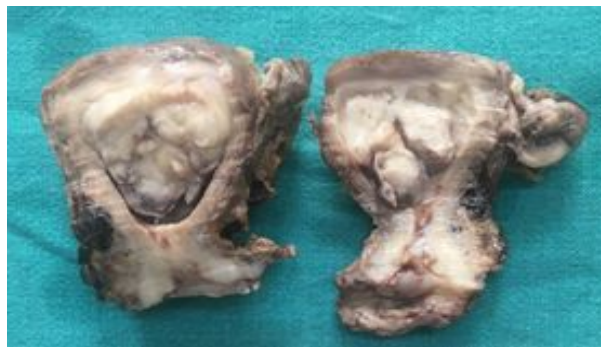


Figure 1: Gross specimen (cut section) of uterus showing dilated endometrial cavity filled with polypoidal lesion measuring 4.5 x 4cm with fleshy and hemorrhagic area. Cervix unremarkable.

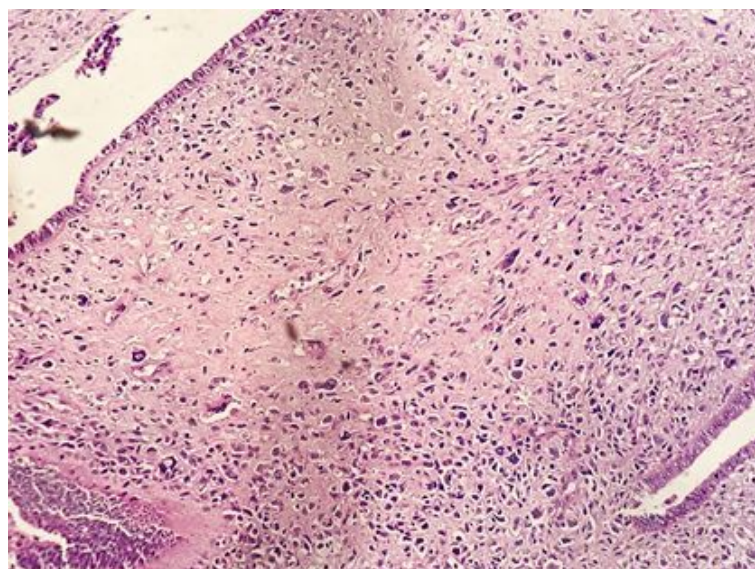


Figure 2: Microscopy (low power) showing an infiltrating neoplasm composed of biphasic component - epithelial and sarcomatous component.

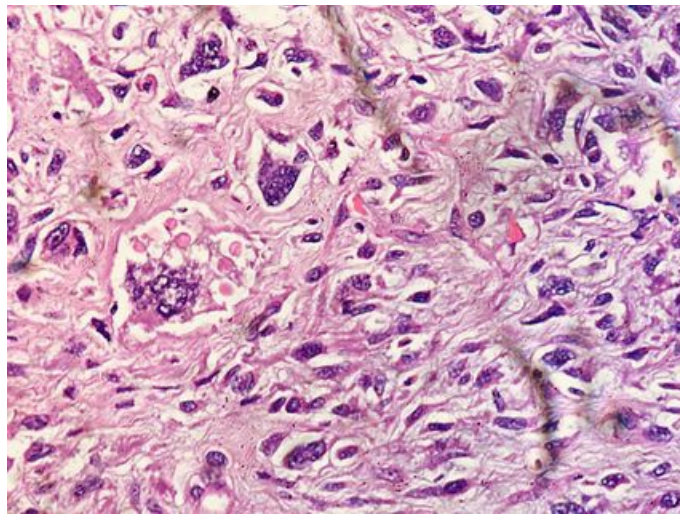


Figure 3: Microscopy (high power) showing multinucleated giant cells.

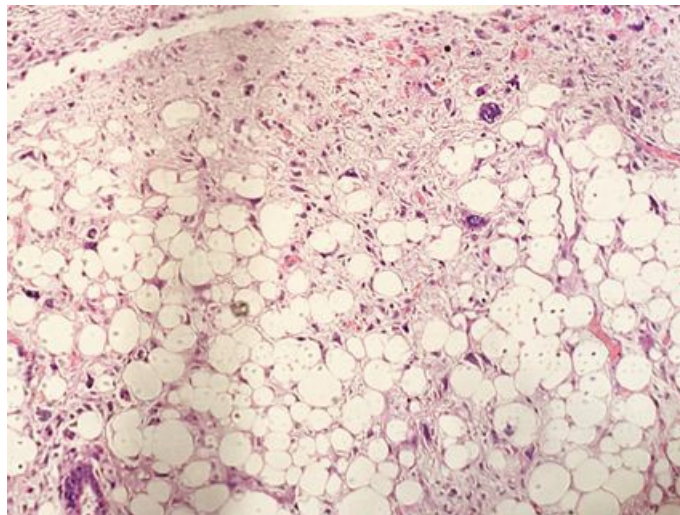


Figure 4: Microscopy showing heterogenous elements like adipocytes lined by atypical lipoblasts (lipoblast).

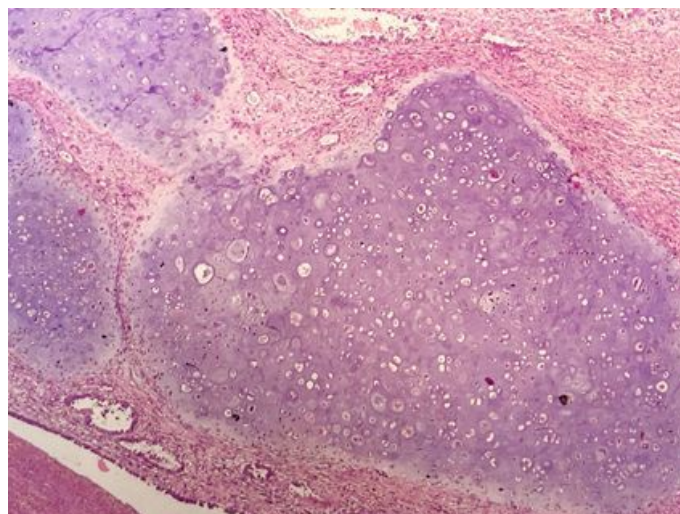


Figure 5: Microscopy showing heterogenous elements like immature cartilage (chondrosarcoma)

Discussion

Uterine carcinosarcoma (UCS), previously known as mixed mesodermal tumor or mixed mullerian tumor, is a rare endometrial neoplasm in which the adenomatous as well as the stromal (mesenchymal) element of the endometrium is malignant. The stromal components of the carcinosarcomas are further characterized by whether they contain homologous elements, such as malignant mesenchymal tissue considered possibly native to the uterus, or heterologous elements, such as striated muscle, cartilage, or bone, which are foreign to the uterus [1-7].

The risk factors for endometrial carcinoma and UCSs are similar namely nulliparity, advanced age, obesity, and estrogen use. The only documented etiologic factor in 10% to 25% of these malignancies is prior pelvic radiation therapy [8]. An increased incidence of uterine sarcoma has been associated with tamoxifen in the treatment of breast cancer [9].

The tumor shows preponderance in postmenopausal women; however, it may occur in premenopausal women as well. The most common presenting symptom is postmenopausal bleeding followed by bloody/watery discharge and abdominal pain. The patient may also complain of abdominal swelling or of increased abdominal girth. In advanced stages, the patient may complain of urinary tract or gastrointestinal symptoms.

The appearance on USG, CT and MRI of UCS is not pathognomonic. The final diagnosis of UCS is established by histopathological tissue examination.

The current 2009 FIGO staging system classifies UCS together with endometrial carcinomas, and its staging is same as in endometrial carcinoma [10]. Disease stage is the most important prognostic factor [11]. Even in stage I, the prognosis of UCS may be worse than in endometrial carcinoma [12].

The most common sites of metastasis are the lung, peritoneum, and pelvic and para-aortic lymph nodes [13].

Surgery is the primary treatment for UCS and includes hysterectomy, bilateral salpingo-oophorectomy, omentectomy and lymph node dissection and resection of all gross disease. Better survival was observed in patients that underwent lymphadenectomy than in those that did not undergo it [14].

Adjuvant treatment is indicated in all stages of UCS since even in stage I, the recurrence rate in patients who do not receive adjuvant therapy may be as high as 50 % [15]. Yet, there is no consensus with regard to the optimal mode of adjuvant treatment (chemotherapy or radiation or both) in women with this tumor. It has been repeatedly found that adjuvant pelvic irradiation or brachy radiotherapy reduce the rate of local recurrences [16].

Adjuvant chemotherapy has been shown to be an effective UCS treatment modality in many studies. A multicenter retrospective study by Cantrell LA et al assessed the impact of adjuvant treatment (including chemotherapy) in a cohort of 111 patients with early stage (stages I-II) UCS [17]. The great majority of the patients (95 %) had stage I disease. Chemotherapy, mostly platinum-based, was given to 26 % of the patients, 20 % underwent radiotherapy, 14 % underwent both radiotherapy and chemotherapy, and 40 % did not receive any adjuvant therapy. Even in stage IA disease, 18 % of 22 patients recurred. Adjuvant chemotherapy was associated with improved outcome compared to radiation or observation alone.

Several studies found that adjuvant paclitaxel and carboplatin is an effective regimen. A three drug combination has also been tried. The combination of carboplatin, paclitaxel, and pegylated liposomal doxorubicin was found to have activity in advanced, persistent, or recurrent UCS with

an acceptable toxicity profile [18]. The overall RR was 62 % (complete response 34 %, partial response 28 %).

The overall prognosis of uterine carcinosarcoma is poor, even with the best of care, due to its aggressive behavior [19]. The surgical stage is the most important prognostic factor, and deep myometrial invasion and extrauterine extension predict poor prognosis [20]. The 5-year survival is 60-75% for uterine-confined disease, 40-60% for early-stage disease (I and II), and 15-30% for late-stage disease, with overall median survival of less than 2 years [20].

Summary

A rare case of uterine carcinosarcoma is reported in this study. Considering the highly invasive nature of uterine carcinosarcomas, timely detection of this cancer using characteristic imaging and pathology findings is of extreme importance to improve the patient's survival.

References

1. R. Arend, J. A. Doneza, and J. D. Wright. Uterine carcinosarcoma. *Current Opinion in Oncology*, vol. 23, no. 5, pp. 531-536, 2011.
2. L. A. Cantrell, S. V. Blank, and L. R. Duska. Uterine carcinosarcoma: a review of the literature. *Gynecologic Oncology*, vol. 137, no. 3, pp. 581-588, 2015.
3. C. L. Chaffer, B. P. San Juan, E. Lim, and R. A. Weinberg. EMT. Cell plasticity and metastasis. *Cancer and Metastasis Reviews*, vol. 35, no. 4, pp. 645-654, 2016.
4. J. A. Somarelli, M.K. Boss, J. I. Epstein, A. J. Armstrong, and M. A. Garcia-Blanco. Carcinosarcomas: tumors in transition? *Histology and Histopathology*, vol. 30, no. 6, pp. 673-687, 2015.
5. A. D. Cherniack, H. Shen, V. Walter et al., Integrated molecular characterization of uterine carcinosarcoma. *Cancer Cell*, vol. 31, no. 3, pp. 411-423, 2017.
6. M. K. McConechy, L. N. Hoang, M. H. Chui et al. In-depth molecular profiling of the biphasic components of uterine carcinosarcomas. *The Journal of Pathology: Clinical Research*, vol. 1, no. 3, pp. 173-185, 2015.
- 7 P. Ravishankar, D. A. Smith, S. Avril, E. Kikano, and N. H. Ramaiya. Uterine carcinosarcoma: a primer for radiologists. *Abdominal Radiology*, vol. 44, no. 8, pp. 2874-2885, 2019.
8. Callister M, Ramondetta LM, Jhingran A, Burke TW, Eifel PJ. Malignant mixed mullerian tumors of the uterus: analysis of patterns of failure, prognostic factors, and treatment outcome. *Int J Radiat Oncol Biol Phys*. 2004;58:786-96.
9. McCluggage WG, Abdulkader M, Price JH, Kelehan P, Hamilton S, Beattie J, et al. Uterine carcinosarcomas in patients receiving tamoxifen. A report of 19 cases. *Int J Gynecol Cancer*. 2000;10:280-4.
10. Pecorelli S. Revised FIGO staging for carcinoma of the vulva, cervix, and endometrium. *Int J Gynaecol Obstet*. 2009;105:103-4.
11. Rovirosa A, Ascaso C, Arenas M, Rios I, Del Pino M, Ordi J, et al. Pathologic prognostic

factors in stage I-III uterine carcinosarcoma treated with postoperative radiotherapy. Arch Gynecol Obstet. 2014;290:329-34.

12. Ferguson SE, Tornos C, Hummer A, Barakat RR, Soslow RA. Prognostic features of surgical stage I uterine carcinosarcoma. Am J Surg Pathol. 2007;31:653-61.

13. McCluggage WG. Uterine carcinosarcomas (malignant mixed Mullerian tumors) are metaplastic carcinomas. Int J Gynecol Cancer. 2002;12:687-90.

14. Hoellen F, Waldmann A, Benthin S, Hanker L, Rody A, Fischer D. The role of lymphadenectomy in uterine sarcoma: a clinical practical approach based on retrospective analysis. Anticancer Res. 2014;34:985-93.

15. Leath 3rd CA, Numnum TM, Kendrick 4th JE, Frederick PJ, Rocconi RP, Conner MG, et al. Patterns of failure for conservatively managed surgical stage I uterine carcinosarcoma: implications for adjuvant therapy. Int J Gynecol Cancer. 2009;19:888-91.

16. Dusenbery KE, Potish RA, Argenta PA, Judson PL. On the apparent failure of adjuvant pelvic radiotherapy to improve survival for women with uterine sarcomas confined to the uterus. Am J Clin Oncol. 2005;28:295-300.

17. Cantrell LA, Havrilesky L, Moore DT, O'Malley D, Liotta M, Secord AA, et al. A multiinstitutional cohort study of adjuvant therapy in stage I-II uterine carcinosarcoma. Gynecol Oncol. 2012;127:22-6.

18. Pectasides D, Pectasides E, Papaxoinis G, Xiros N, Sykiotis C, Papachristodoulou A, et al. Combination chemotherapy with carboplatin, paclitaxel and pegylated liposomal doxorubicin for advanced or recurrent carcinosarcoma of the uterus: clinical experience of a single institution. Gynecol Oncol. 2008;110:299-303.

19. K. Harano, A. Hirakawa, M. Yunokawa et al. Prognostic factors in patients with uterine carcinosarcoma: a multiinstitutional retrospective study from the Japanese Gynecologic Oncology Group. International Journal of Clinical Oncology, vol. 21, no. 1, pp. 168-176, 2016.

20. N. Bansal, T. J. Herzog, V. E. Seshan et al. Uterine carcinosarcomas and grade 3 endometrioid cancers: evidence for distinct tumor behavior, Obstetrics and Gynecology, vol. 112, no. 1, pp. 64-70, 2008.